

Ocular disease in the guinea pig (*Cavia porcellus*): a survey of 1000 animals

David Williams and Ann Sullivan

Department of Veterinary Medicine, University of Cambridge, Cambridge CB3 0ES, UK

Address communications to:

D. Williams

Tel.: 07939 074682

Fax: +44-1223-232977

e-mail: dlw33@cam.ac.uk

Abstract

Objective Anecdotal evidence has suggested that guinea pigs have a high prevalence of ocular lesions. Here we undertook a survey of 1000 guinea pigs from populations of animals kept as laboratory animals, breeding show cavies, animals kept as pets and those from rescue and rehoming centers. Each animal was examined to assess for ocular abnormalities.

Procedures A full ophthalmic examination was performed on each animal with direct and indirect ophthalmoscopy and with slit lamp biomicroscopy. Measurement of tear production using the Schirmer tear test 1 and intraocular pressure using the Tonopen applanation tonometer after topical anesthesia was undertaken in selected animals.

Results Forty-five percent of animals examined had some ocular abnormality. The majority were lens lesions including 17% with cataract and 21% with subclinical lens abnormalities such as nuclear sclerosis. Other abnormalities included conjunctivitis in 4.7% and keratitis in 3.6%. Lipid deposition in conjunctiva was observed in 2.3% of guinea pigs and ciliary body heterotopic bone formation in 0.8% of animals.

Conclusions This study shows a high proportion of eyes with some degree of abnormality in animals otherwise considered healthy. Information on diseases of the guinea pig eye is important given the use of the species as a laboratory rodent and also the number kept as pets and show animals.

Key Words: cataract, *Cavia porcellus*, disease, eye, guinea pig, prevalence

INTRODUCTION

The guinea pig has been used for many years as a laboratory rodent, to the extent that its very name is used as a term denoting experimental subject. Much of this study has been devoted to ophthalmic research ranging from infectious ocular surface disease^{1–3} through external and internal intra-ocular inflammation,^{4–8} development of myopia,^{9,10} the generation of cataract^{11,12} (especially given the guinea pig requirement for dietary ascorbic acid¹³) through to retinal physiology and pathology given the avascular nature of the guinea pig retina.¹⁴ Yet to date no evaluation has been made of the prevalence of ocular disease in a large population of normal guinea pigs, a species widely kept as a small companion animal and particularly as a children's pet. Veterinary ophthalmologists see a number of guinea pigs with conjunctivitis, cataract, glaucoma, and a number of other ocular conditions. Here we report the findings of a survey of 1000 guinea pigs from several populations; two laboratory colonies, several show animals in breeding establishments, many pet guinea pigs and a large number in rescue and rehoming

centers. It seems remarkable to the present authors that large collections of guinea pigs, sometimes well in excess of one hundred in one center, are kept not only in laboratories but by those breeding for showing or in centers rescuing and rehoming pet guinea pigs. It was these large populations which allowed us to evaluate 1000 animals with relative ease.

MATERIALS AND METHODS

The guinea pigs were examined in two laboratory facilities (46 Duncan-Hartley, 30 outbred short-haired), in facilities specifically breeding pedigree animals for show (48 American crested, 56 Abyssinian, 68 English Smooth Coat, 47 Peruvian) in individual homes (226 of various breeds) and in rescue and rehoming centers (479 of various breeds). All animals had free access to food, either a commercial pellet in the laboratory and breeding facilities with supplemental vitamin C or copious fresh green vegetable and hay in the case of pets owned at home or kept in rescue and rehoming centers.

Animals underwent a full ophthalmic examination with direct and indirect ophthalmoscopy together with slit lamp biomicroscopy. Schirmer tear test (STT) evaluation of tear production (Schering-Plough Animal Health, Union, NJ batch 2051527) was performed (Fig. 1) where ocular surface disease was present and in 50 randomly chosen guinea pigs for evaluation of normal tear production.¹⁵ Tonometry using a Tonopen Applanation tonometer (Tonopen XL Carlton Optical Products, Watford) after topical anesthesia using tetracaine hydrochloride (Tetracaine, Minims; Chauvin pharmaceuticals, Romford) was performed where glaucoma or uveitis was suspected and in 100 normal guinea pigs to provide a normal reference range against which to compare intraocular pressure in abnormal eyes. As neither STTs nor intraocular pressures were significantly different between eyes of individual animals using a paired *t*-test, an average of both eyes was used, although the authors understand that data may be lost using such an averaging procedure.¹⁶ Differences between STTs or intraocular pressures in normal and abnormal eyes were evaluated using an unpaired *t*-test. Differences in ages were compared using a Mann-Whitney *U*-test as these data were not normally distributed.

Photographic documentation was provided using a Coolpix 4500 digital camera (Nikon, Chiyoda-ku, Tokyo, Japan) for external photography and a Keeler Genesis D digital fundus camera (Keeler corporation, Windsor, UK) for photography intraocular structures.

RESULTS

The mean age of the animals examined for which an accurate age was available (834 animals) was 2.9 ± 1.7 years. All figures given herein are mean \pm SD. The laboratory animals were significantly younger (1.9 ± 0.6 years) as were the breeding show individuals (2.3 ± 1.1 years) while the animals from rescue and rehoming shelters were, where an

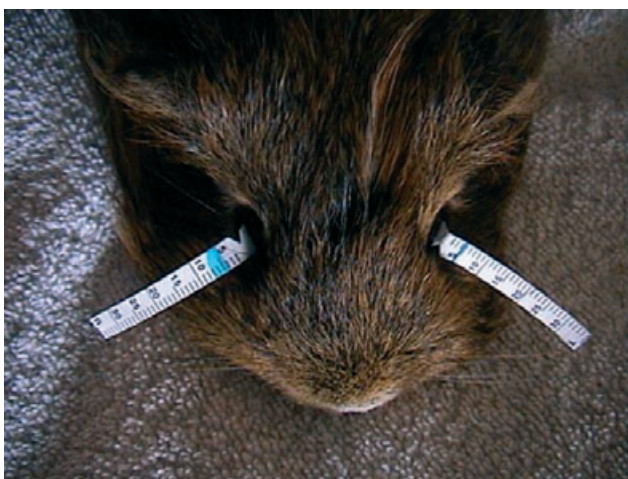

Figure 1. Schirmer tear test (STT) in guinea pig with unilateral left keratoconjunctivitis sicca and a zero STT reading.

Table 1. Number and percentage of animals and eyes affected by ocular abnormalities

Condition	Number of animals affected (%)	Number of eyes affected (%)
Anophthalmos	1 (0.1)	2 (0.1)
Microphthalmos	8 (0.8)	16 (0.8)
Congenital trichiasis	8 (0.8)	16 (0.8)
Conjunctivitis	47 (4.7)	67 (3.4)
White ocular discharge	4 (0.4)	8 (0.4)
Keratoconjunctivitis sicca	3 (0.3)	6 (0.3)
Ocular trauma	22 (2.2)	25 (1.25)
Cataract	174 (17.4)	338 (16.9)
Congenital cataract	37 (3.7)	74 (3.7)
Nuclear sclerosis	205 (10.5)	410 (10.5)
Nuclear rings	81 (8.1)	159 (7.9)
Incipient cataract	53 (5.3)	44 (2.2)
Immature cataract	50 (5.0)	98 (4.9)
Mature cataract	34 (3.4)	68 (3.4)
Diabetic cataract	27 (2.7)	54 (2.7)
Heterotopic bone formation	8 (0.8)	12 (0.6)
Conjunctival lipid deposition 'fatty eye'	23 (2.3)	38 (1.9)
Prolapsed nictitans gland 'flesh eye'	5 (0.5)	8 (0.4)

exact age was available, substantially although not statistically older (3.9 ± 2.0 years). A total of 1000 animals have been used for this study, of those 532 were female and 468 male.

Of 1000 animals examined, 446 had some ocular abnormality (Table 1). The majority of these were lens changes (Fig. 2) with 174 having cataract and 286 exhibiting other lens pathology such as nuclear sclerosis with or without concurrent cataract (205 animals, 410 eyes) or single or double nuclear rings (81 animals, 159 eyes). Of the animals with cataract 34 had bilaterally mature lens opacities with 27 of these having diabetes, this defined with a diagnosis of polydipsia and polyuria and a urine glucose of over 100 mg/L. Thirty seven cataractous cavies were young animals with apparently congenital cataract and of these 12 were closely related from one in-bred family. Those animals with mature or developing immature cataract were on average older than the mean age of the total population (3.8 ± 0.8 years compared with 2.9 ± 1.7 years although these were not significantly different $P = 0.08$).

Forty-seven animals showed some degree of conjunctivitis while 36 animals exhibited keratitis. Conjunctivitis eyes typically had conjunctival hyperemia and some chemosis. In 25 animals there was a history of previous injury with a hay or straw shard with a focal injury being evident in 15 eyes (Fig. 3) or a proliferative conjunctivitis in two (Fig. 3c). Keratitis associated with decreased tear production and a lower than the normal STT value (<1 mm/min compared with 3.8 ± 1.3 mm/min in 50 individuals with unremarkable ocular surfaces) was seen in three animals (Fig. 4). A small number of cavies (four in total) showed an aberrantly high secretion of white fluid from the conjunctival sac (Fig. 5) but were in other respects normal without other signs of

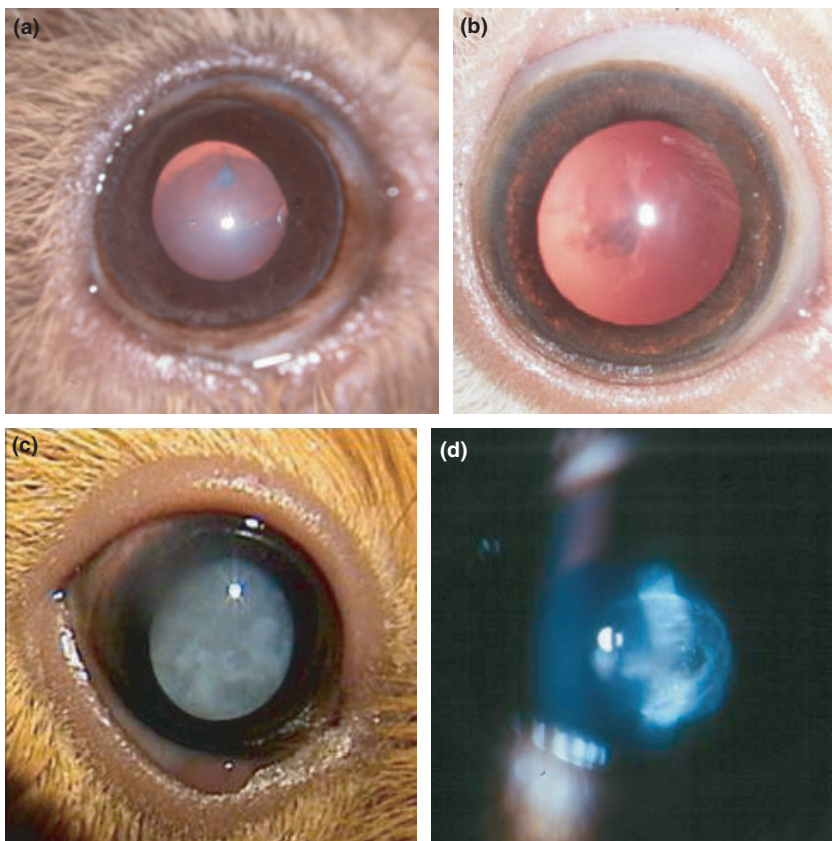


Figure 2. Lens changes in guinea pigs. (a) Nuclear sclerosis and a focal anterior cortical opacity in a 5-year-old animal, (b) nuclear opacities in a 4-year-old animal, (c) mature diabetic cataract in a 3-year-old animal with concurrent conjunctival lipid deposit, (d) slit lamp image of a posterior axial subcapsular opacity in a 6-month-old animal.

conjunctivitis. Microscopic analysis of the fluid did not show an elevated number of inflammatory cells but merely occasional squamous epitheliocytes, demonstrating that this fluid is not associated with ocular surface inflammation.

Congenital abnormalities were more common than was expected with microphthalmos or anophthalmos occurring in 16 animals. One Rex male showed clinical anophthalmos with no globe structure observable (Fig. 6) while eight related animals had microphthalmos with keratitis (Fig. 7). Abyssinian guinea pigs were particularly frequently noted to have microphthalmos and cataract with five roan \times roan animals being thus affected (Fig. 8), statistically a higher number than for any other breed ($P < 0.05$). Eight neonatal Texel cavies were affected with trichiasis (Fig. 9) and in five cases where this had not been corrected early in life there was subsequent chronic keratitis. Three guinea pigs with abundant nasal fold hair also showed trichiasis although keratitis was less marked in these cases (Fig. 10).

Heterotopic bone formation, although widely reported in the literature¹⁷ was only seen in 12 eyes of eight individuals (Fig. 11). Intraocular pressure in eyes thus affected was 15.3 ± 4.2 mmHg compared with a value of 16.5 ± 3.2 mmHg in 100 eyes without the condition.

Lipid deposition in the conjunctiva of the lower eyelid (Fig. 12), termed fatty eye by guinea pig breeders, was seen in 23 animals, 20 of these being show individuals many of which were somewhat overweight through being fed for the

show ring (Fig. 12a). Corneal lipid deposition was noted unilaterally in two of these individuals and bilaterally in two other guinea pigs (Fig. 13). Five animals exhibited a discrete pink mass in the medial canthus (Fig. 14), termed “flesh eye” by the guinea pig fraternity and most probably a prolapse of the nictitans gland. Histological confirmation of this was not possible through lack of owner consent to excisional surgery or biopsy given that the condition did not appear to compromise the animals’ vision or ocular comfort.

DISCUSSION

The high prevalence of ocular disease seen in the guinea pigs examined in this study was surprising as this has not been reported previously. Many of these conditions, however, did not appear to have a significant impact of the animals’ health or behavior and, being visible only on close ophthalmic examination, would not have been noted by owners and presented to veterinarians.

The prevalence of lens opacity was noteworthy. Many of these animals had incipient or immature cataract and the majority of these occurred in older animals. A small proportion were mature cataracts, often seen in diabetic animals, although without a study specifically examining diabetic guinea pigs the prevalence of cataract in that population cannot be ascertained with any certainty. A small group were animals with congenital cataract. The literature demonstrates

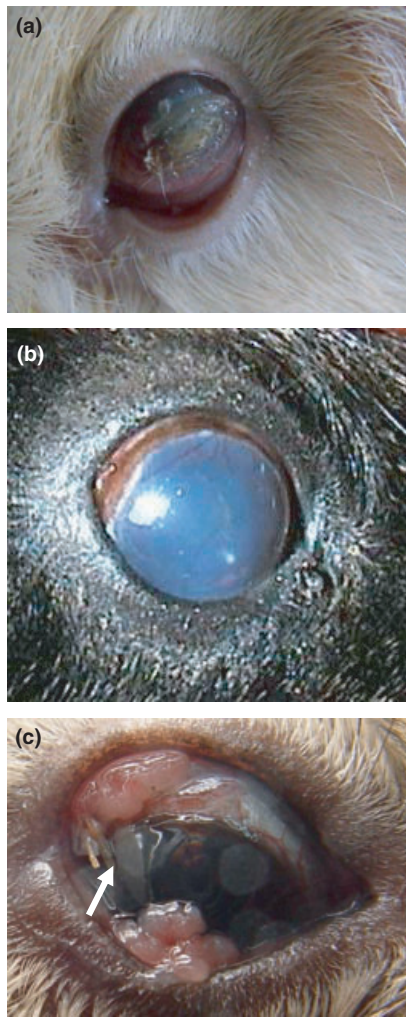


Figure 3. Traumatic corneal lesions in guinea pigs. (a) Recent hay awn trauma with irregular ulcerated corneal surface, (b) healed penetrating trauma with white scar at point of entry but secondary uveitis and glaucoma giving generalized corneal edema, (c) proliferative inflammatory conjunctival reaction to hay awn still visible in conjunctival fornix (white arrow) Courtesy Children’s Zoo, Zoological Society of London.

that some specific strains have a particular developmental lens opacity and it may be that the family of guinea pigs in which a high proportion had cataract have the same or a similar genetic mutation giving the lens opacity. The N13 strain of guinea pigs has a congenital nuclear cataract¹⁸ associated with a mutation in the zeta crystalline gene¹² through which the crystallin, a zinc-containing alcohol dehydrogenase, fails to bind zinc at its core,¹⁹ this leading to a complete lack of zeta crystalline mRNA in homozygote affected lenses.²⁰ Chaperone molecules cannot refold the mutant zeta crystalline, rendering it prone to aggregation.²¹

The welfare of animals blind with mature cataract did not appear overly compromised: behavior such as foraging for food, negotiating objects in familiar territory and interacting with familiar cage-mates was no different from that observed

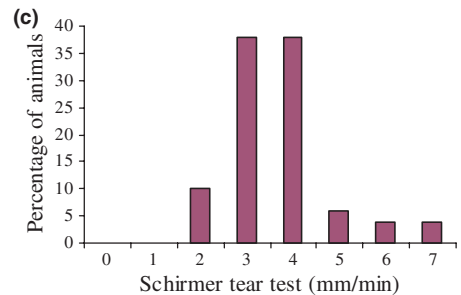
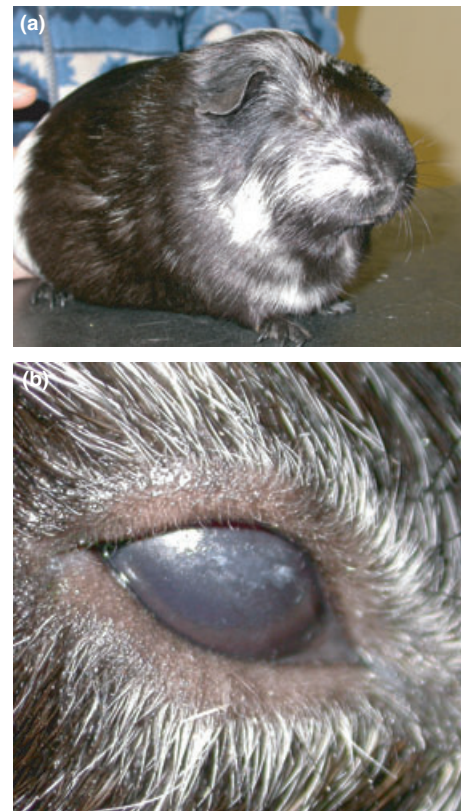

Figure 4. Keratoconjunctivitis sicca in a guinea pig with an Schirmer tear test of 0 mm/min. (a) Blepharospasm showing ocular discomfort, (b) ocular surface drying shown by break-up of light reflection, (c) Schirmer tear test values in fifty normal guinea pigs.

with normally sighted cage-mates and thus removal of these opaque lenses was not attempted.

The same cannot be said for some of the animals with congenital defects. Microphthalmos and anophthalmos are noted with higher frequency in guinea pigs than seems to have been reported in other species barring inbred laboratory rats and mice. This is particularly true in the Abyssinian breed and in color dilute crosses such as the roan/roan cross shown in Fig. 8. Previous reports have documented anophthalmos as a heritable trait,²² and as occurring after pyrexia during gestation,²³ but no such previous history was apparent for the animal affected in this study. While blindness appears not to be an obstacle to a happy healthy guinea pig life, the ocular surface irritation occasioned by trichiasis as seen in Texel cavies such as those in Fig. 9 is highly aggra-

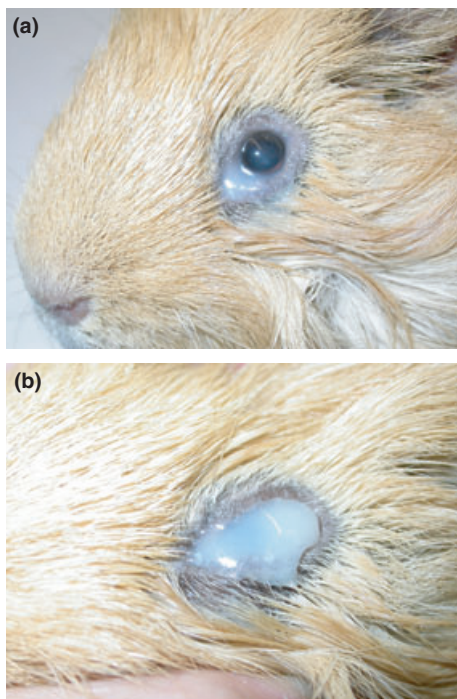


Figure 5. White discharge from an otherwise normal guinea pig eye. (a) Mild discharge at medial canthus on initial presentation, (b) copious discharge obscuring visual axis 1 h after Fig. 5a.



Figure 6. Anophthalmos in one rex guinea pig.

vating to the animals. Guinea pig breeders with texels know to use Vaseline or a similar lubricant early in life to smooth the aberrant hairs away from the ocular surface to avoid the sort of longstanding corneal damage seen as a result of long-standing trichiasis. A more frequent source of corneal damage is the hay and straw which can cause profound ocular surface irritation as in Fig. 3a or direct corneal trauma as in Fig. 3b. A relatively high number of animals had signs of ocular surface trauma, either recent, two with foreign bodies still present (Fig. 3c) or with long term scarring (Fig. 3b). Three animals had keratitis associated with low or absent tear production with STT values of zero (Fig. 4). We

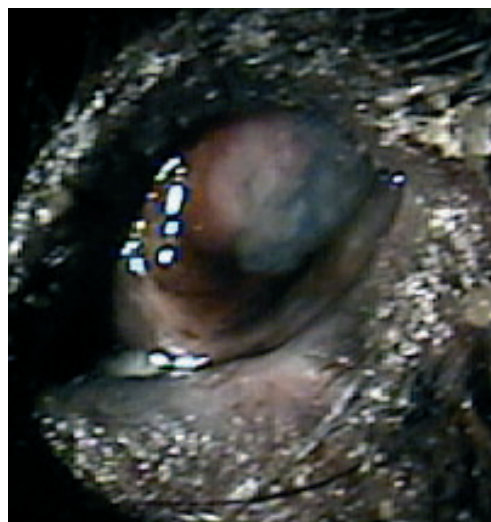

Figure 7. Microphthalmos with keratitis in a 2-month-old guinea pig.

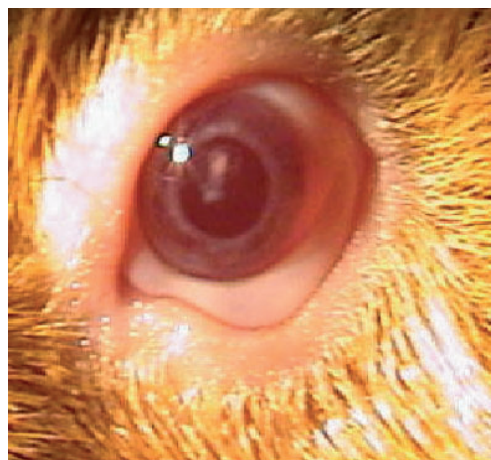

Figure 8. Mild microphthalmos and cataract in an Abyssinian roan × roan guinea.

measured STT values for 50 randomly selected guinea pigs with normal eyes and showed a value of 3.8 ± 1.3 mm/min (Fig. 4c). Two recent studies have given substantially different mean values for STT in guinea pigs. Coster and associates²⁴ measured STT in 31 healthy guinea pigs and found a median value of 3 mm/min with a range of 0–11 mm/min.




Figure 9. Trichiasis in a young texel guinea pig with associated keratitis. (a) Ocular surface showing trichiasis and keratitis, (b) guinea pig showing hair coat texture.

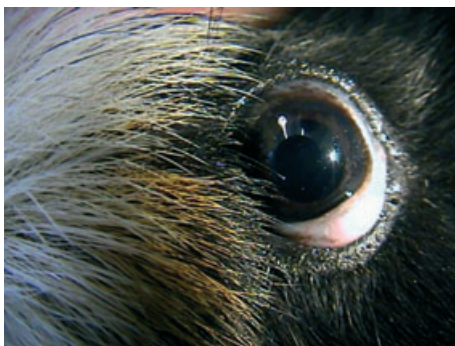


Figure 10. Guinea pig with abundant nasal fold hair giving mild trichiasis.

Trost *et al.*,¹⁵ measured STT in 54 adult albino laboratory Duncan-Hartley guinea pigs aged 2.5 years and found a surprisingly low mean value of 0.36 ± 1.1 mm/min with a reference range of -1.78 to 2.5 mm/min. Our mean value of 3.8 mm/min is more similar to that of Coster's report than Trost's which may relate to the breed specificity of the latter. Previous work on tear production in rabbits²⁵ has shown that different breeds can have substantially varying STT values and the same may be the case in guinea pigs; here is an opportunity for further research. Only three animals in this

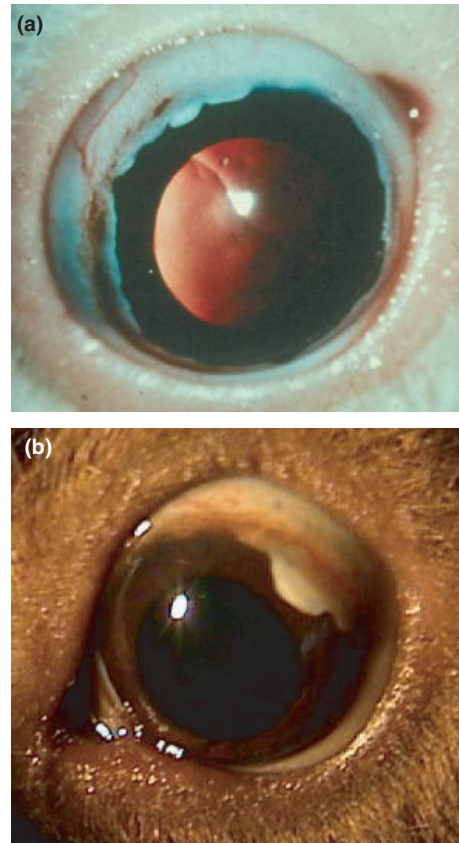


Figure 11. Heterotopic bone formation. (a) involving a large proportion of the limbus, (b) only as one small area of ossification.

study had overt keratoconjunctivitis sicca (KCS) but it must be emphasized that these were animals not presented because of ocular disease but from the normal pet population. We did not recognize keratitis associated with facial nerve palsy as reported recently in a guinea pig with corneal ulceration and scarring.²⁶ Both previous reports noted guinea pigs with zero STT readings and normal eyes, as is also seen in cats by the current senior author. KCS may be defined as a low tear production with associated ocular surface pathology, as noted here (Fig. 4b).

Relatively few animals had conjunctivitis without other ocular abnormalities such as microphthalmos or trichiasis compared with the number of studies on guinea pig conjunctivitis in the experimental ophthalmic literature. Most of these were either an induced allergic conjunctivitis or one associated with *Chlamydia* (now *Chlamydophila*) *caviae*.⁵ Such predominance of reports in the scientific literature concerning induced conjunctivitis gives the impression that the condition is more prevalent than shown here, and demonstrates the importance of large-scale epidemiological studies, as presented here, in assessing the prevalence of disease in the normal cavy population.

Profuse white ocular discharge was noted in four cavies; this might be considered by many as a sign of ocular disease but is in fact a normal finding. All guinea pigs can produce

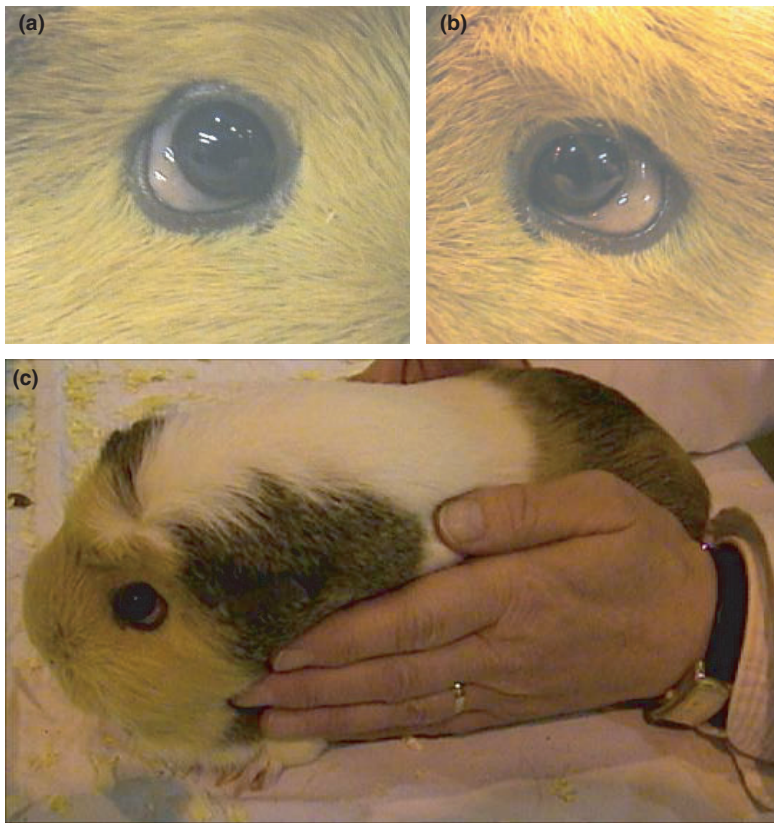

Figure 12. Lipid deposition in the conjunctiva or 'fatty eye.' (a, b) Inferior conjunctival lipid deposition in both eyes of a 3-year-old guinea pig. (c) The animal itself, presented at a cavy show, showing what some would describe as excellent show condition or what might otherwise be termed obesity.

this white fluid and use it in grooming although in some it appears to be produced in excess, without concurrent finding of conjunctival inflammation.²⁷

A condition which has been reported several times in the veterinary literature is heterotopic bone formation,^{14,28} or as it was first termed, osseous choristoma.²⁹ This condition, a white lesion at the limbus which corresponds to new bone formation in the ciliary body, was seen in only eight guinea pigs in the current study. Previous reports have suggested an association between heterotopic bone formation and glaucoma,³⁰ although this correlation was made at postmortem and not with measurement of intraocular pressure in affected and matched normal animals *in vivo*. In this small number of cases there was no rise in intraocular pressure (15.3 ± 4.2 mmHg) compared with the tonometric values obtained in normal animals (16.5 ± 3.2 mmHg), although it has to be said that these were not matched for age, gender or breed. The formation of this heterotopic bone probably occurs as a result of vitamin C secretion in to the aqueous by the ciliary body since increased levels of ascorbate can lead to bone deposition.¹⁵ Animals over-supplemented with ascorbate might be considered more likely to develop this condition, but careful history taking with regard to these cases seen here did not lead to the suggestion that there was anything abnormal about the management of these animals compared to unaffected guinea pigs.

This is not the case with animals in which deposition of lipid occurred in the inferior conjunctiva of a number of guinea pigs in this study. This condition was seen

predominantly but not exclusively in animals well fed prior to entry into a guinea pig show or competition. These animals generally have a high body condition score as seen in Fig. 12c. Exhibitors tread a fine line between having a 'well rounded' animal, favored by judges and one with 'fatty eye' which is considered a detriment. Another lesion of lipid deposition occurs in the cornea (Fig. 13) and may be seen concurrent with conjunctival lipid deposition. Corneal lipidosis is also seen as a bilateral condition, presumably a stromal lipid dystrophy similar to that seen in dogs. The bilaterally and central corneal appearance of this crystalline lipid deposition suggests similarity to inherited lipid dystrophy in other species although heritability has yet to be proven. Indeed one of the disadvantages of many of these animals being seen in rescue and rehoming centers is that there is no hereditary information on these animals, necessary for the evaluation of such corneal lipid depositions as possible dystrophies, where inheritance is a key feature.

Another lesion in the conjunctiva is so-called flesh eye, a pink 'flesh colored' mass at the medial canthus (Fig. 14) which appears similar to the prolapsed nictitans gland seen in the dog.³¹ Surgical removal under a general anesthetic and histological evaluation would allow a definitive diagnosis of the exact nature of the tissue is, but to date this has not been possible.

A further point for discussion is that the high prevalence of ocular lesions is seen predominantly in outbred animals encountered as pets and not in pedigree show animals. The

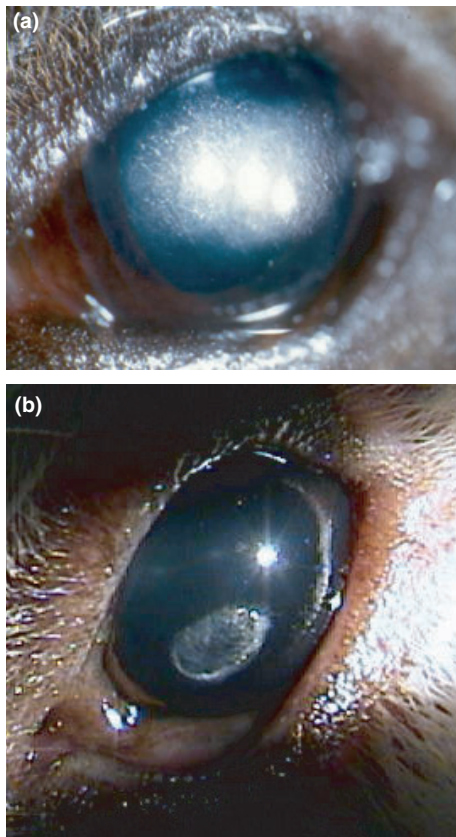


Figure 13. Corneal lipid deposition. (a) Extensive crystalline lipid bilateral paracentral deposition in a 3-year-old animal, (b) less marked oval lipid deposition in a 5-year-old animal.

general pet population as seen here in rescue and rehoming shelter animals is outbred compared to pedigree breeds from the American crested to the Abyssinian. These animals are line-bred to a degree quite as high as that encountered in dog breeding. Why, it might be asked, is it that these animals have very few ocular lesions such as cataracts and globe or lid defects, compared with the outbred pet animals? In the dog or cat exactly the opposite occurs with line-bred pedigree animals having a substantially greater number of abnormalities either specifically bred for or resulting from the reduction in genetic diversity in these highly inbred animals. Given that the majority of abnormalities in the present study are lens opacities, perhaps the requirement for dietary vitamin C is the key to this prevalence of lens opacities. Even where supplementation appears to be sufficient, maybe the guinea pig and not the rabbit fed on a similar diet, undergoes lenticular oxidative stress which results in these cataracts.

Finally it must be said that a survey, even of 1000 animals, cannot hope to demonstrate every condition of note in a specific organ system. And thus in the animals examined here we did not encounter a dermoid, though several reports exist in the literature of this condition in the guinea pig.^{32–34} But what such a study can demonstrate is the prevalence of specific conditions in a species and ask as many questions as it

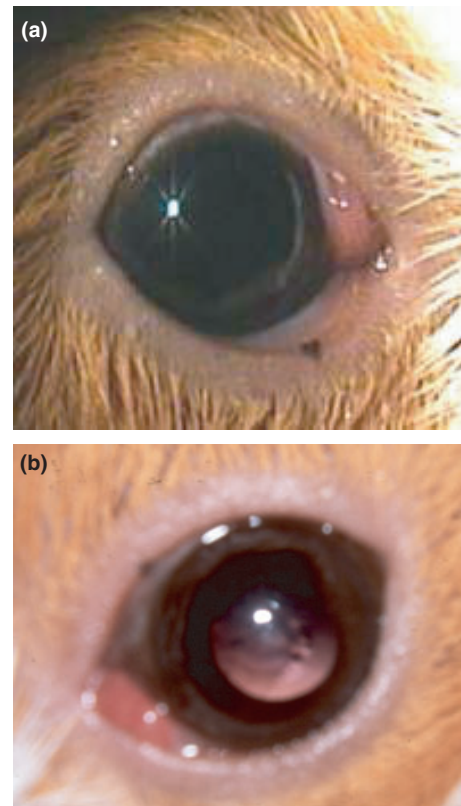


Figure 14 ‘Flesh eye’ (a) Unilateral medial canthal mass in right eye of a 3-year-old male guinea pig, (b) unilateral medial canthal mass in the left eye of a 4-year-old female guinea pig note also the central nuclear cataract, bilateral in this animal.

answers, hopefully fueling further research in guinea pig ophthalmology.

CONCLUSION

We have shown an unusually high prevalence of ocular lesions in the normal guinea pig population. These findings are important given the use of this species in experimental studies and the number kept as pets and show animals. The high prevalence of cataracts in these animals compared with pet rabbits kept under identical conditions with a similar diet may suggest a worthwhile area of study investigating the reasons for these marked differences.

ACKNOWLEDGMENTS

The owners of the guinea pigs involved in this study are thanked sincerely for their assistance in examination of their charges as are the veterinarians who introduced us to their cavy clients, many of whom provide an unparalleled service in rescuing and caring for tens and sometimes hundreds of guinea pigs. Figures 2c,6,8a,9a,11a are reproduced from my laboratory animals chapter in Gelatt’s *Veterinary Ophthalmology*.³⁵

REFERENCES

1. Vijay AK, Sankaridurg P, Zhu H *et al.* Guinea pig models of acute keratitis responses. *Cornea* 2009; **28**: 1153–1159.
2. Watkins NG, Hadlow WJ, Moos AB *et al.* Ocular delayed hypersensitivity: a pathogenetic mechanism of chlamydial-conjunctivitis in guinea pigs. *Proceedings of the National Academy of Sciences USA* 1986; **83**: 7480–7484.
3. Lutz-Wohlgroth L, Becker A, Brugnera E *et al.* Chlamydiales in guinea-pigs and their zoonotic potential. *Journal of Veterinary Medicine A Physiology, Pathology and Medicine* 2006; **53**: 185–193.
4. Kazdan JJ, Schachter J, Okumoto M. Inclusion conjunctivitis in the guinea pig. *American Journal of Ophthalmology* 1967; **64**: 116–124.
5. Beauregard C, Stephens D, Roberts L *et al.* Duration of action of topical antiallergy drugs in a Guinea pig model of histamine-induced conjunctival vascular permeability. *Journal of Ocular Pharmacology and Therapeutics* 2007; **23**: 315–320.
6. Blyth WA. Infection in guinea-pigs produced by trachoma and inclusion conjunctivitis agents. *British Journal of Experimental Pathology* 1967; **48**: 142–149.
7. Rao NA, Albin TA, Kumaradas M *et al.* Experimental ocular tuberculosis in guinea pigs. *Archives of Ophthalmology* 2009; **127**: 1162–1166.
8. Kükner A, Colakoglu N, Serin D *et al.* Effects of intraperitoneal vitamin E, melatonin and aprotinin on leptin expression in the guinea pig eye during experimental uveitis. *Acta Ophthalmologica Scandinavica* 2006; **84**: 54–61.
9. Lu F, Zhou X, Jiang L *et al.* Axial myopia induced by hyperopic defocus in guinea pigs: a detailed assessment on susceptibility and recovery. *Experimental Eye Research* 2009; **89**: 101–108.
10. Jiang L, Schaeffel F, Zhou X *et al.* Spontaneous axial myopia and emmetropization in a strain of wild-type guinea pig (*Cavia porcellus*). *Investigative Ophthalmology and Visual Science* 2009; **50**: 1013–1019.
11. Bettelheim FA, Churchill AC, Zigler JS Jr. On the nature of hereditary cataract in strain 13/N guinea pigs. *Current Eye Research* 1997; **16**: 917–924.
12. Huang QL, Du XY, Stone SH *et al.* Association of hereditary cataracts in strain 13/N guinea-pigs with mutation of the gene for zeta-crystallin. *Experimental Eye Research* 1990; **50**: 317–325.
13. Wu K, Kojima M, Shui YB *et al.* Ultraviolet B-induced corneal and lens damage in guinea pigs on low-ascorbic acid diet. *Ophthalmic Research* 2004; **36**: 277–283.
14. Racine J, Joly S, Rufiange M *et al.* The photopic ERG of the albino guinea pig (*Cavia porcellus*): a model of the human photopic ERG. *Documenta Ophthalmologica* 2005; **110**: 67–77.
15. Trost K, Skalicky M, Nell B. Schirmer tear test, phenol red thread tear test, eye blink frequency and corneal sensitivity in the guinea pig. *Veterinary Ophthalmology* 2007; **10**: 143–146.
16. Newcombe RG, Duff GR. Eyes or patients? Traps for the unwary in the statistical analysis of ophthalmological studies. *British Journal of Ophthalmology* 1987; **71**: 645–646.
17. Brooks DE, McCracken MD, Collins BR. Heterotopic bone formation in the ciliary body of an aged guinea pig. *Laboratory Animal Science* 1990; **40**: 88–90.
18. Le Nihouannen D, Barralet JE, Fong JE *et al.* Ascorbic acid accelerates osteoclast formation and death. *Bone* 2010; **46**: 1336–1343.
19. Rodriguez IR, Gonzalez P, Zigler JS Jr *et al.* A guinea-pig hereditary cataract contains a splice-site deletion in a crystallin gene. *Biochimica Biophysica Acta* 1991; **1180**: 44–52.
20. Borrás T, Jörnvall H, Rodokanaki A *et al.* The transcripts of zeta-crystallin, a lens protein related to the alcohol dehydrogenase family, are altered in a guinea-pig hereditary cataract. *Experimental Eye Research* 1990; **50**: 729–735.
21. Goenka S, Rao CM. Inability of chaperones to fold mutant zeta crystallin, an aggregation-prone eye lens protein. *Molecular Vision* 2000; **6**: 232–236.
22. Komich RJ. Anophthalmos: an inherited trait in a new stock of guinea pigs. *American Journal of Veterinary Research* 1971; **32**: 2099–2105.
23. Cawdell-Smith J, Upfold J, Edwards M *et al.* Neural tube and other developmental anomalies in the guinea pig following maternal hyperthermia during early neural tube development. *Teratogenicity Carcinogenesis and Mutagenesis* 1992; **12**: 1–9.
24. Coster ME, Stiles J, Krohne SG *et al.* Results of diagnostic ophthalmic testing in healthy guinea pigs. *Journal of the American Veterinary Medical Association* 2008; **232**: 1825–1833.
25. Abrams KL, Brooks DE, Funk RS *et al.* Evaluation of Schirmer tear test in clinically normal rabbits. *American Journal of Veterinary Research* 1990; **51**: 1912–1913.
26. Grahm BH, McRuer DL, Sandmeyer LS. Diagnostic ophthalmology ophtalmologie diagnostique. *Canadian Veterinary Journal* 2007; **48**: 755–756.
27. Richardson V. *Diseases of Domestic Guinea Pigs*. Blackwell, Oxford, 1992.
28. Donnelly TM, Brown C, Donnelly TM. Heterotopic bone in the eyes of a guinea pig: osseous choristoma of the ciliary body. *Laboratory Animals* 2002; **31**: 23–25.
29. Griffith JW, Sassani JW, Bowman TA *et al.* Osseous choristoma of the ciliary body in guinea pigs. *Veterinary Pathology* 1998; **25**: 100–102.
30. Schaffer EH, Pfliegerhaa S. Secondary open angle glaucoma by osseous choristoma of the ciliary body in guinea pigs. *Tierärztliche Praxis* 1995; **23**: 410–414.
31. Morgan RV, Duddy JM, McClurg K. Prolapse of the gland of the third eyelid in dogs. A retrospective study of 89 cases (1980–90). *Journal of the American Animal Hospital Association* 1993; **29**: 56–60.
32. Otto G, Lipman N, Murphy JC. Corneal dermoid in a hairless guinea pig. *Laboratory Animal Science* 1991; **41**: 171–172.
33. Gupta BN. Scleral dermoid in a guinea pig. *Laboratory Animal Science* 1972; **22**: 919–921.
34. Chan E. A corneoscleral dermoid in a guinea pig. *American Journal of Ophthalmology* 1932; **15**: 525–526.
35. Williams DL. Laboratory animal ophthalmology. In: *Veterinary Ophthalmology*. (ed. Gelatt KN) Blackwell Publishing, Iowa, 2007, 1336–1369.